

# Equine Thermography

Martin Collishaw

Progex Equine Infrared, 58 Carr Lane, Willerby, East Yorkshire, HU10 6JW.  
Tel: 01482 656244 | Mob: 07905 486004  
info@equineinfrared.co.uk

## Equine Thermography

Infrared Thermography is a non-invasive monitoring tool that uses the very latest Infrared imaging equipment and computer software to detect small differences in the horse's thermal condition and allows us to quickly and efficiently identify abnormal thermal patterns that may be related to injury or disease. By identifying abnormal patterns, often before other clinical signs are apparent, investigation can be instigated at an earlier stage. Early identification of injury or disease may prevent development of more severe conditions, and also allow monitoring of horses during the recovery process. Infrared Thermography also offers the trainer or rider the opportunity to monitor the effects of training before, during and after competition.

Previous research in human and equine fields has demonstrated that many injuries and physical conditions can be accurately detected using Infrared Thermography, even before any physical signs and symptoms are visibly apparent. Feeling the horse's legs for signs of heat is universal, however the hand can only detect heat where there is a 3-4° difference in temperature from what is considered to be normal and by this stage the damage is more severe. Because Thermography measures minute changes in the thermal and neural conditions it allows for the vet to be called earlier to diagnose problems therefore preventing serious injury trauma and stress to the animal. Infrared Thermography also provides a unique way to monitor a horse's recovery from intense activity, injury and illness.

Recent improvements in Infrared camera technology and supporting software have now enabled us to further investigate potential uses and applications in equine monitoring.

Our objective in this study is to establish normal thermal patterns in horses under controlled conditions and the effects of environment on those patterns using the latest technology. This will then allow us to identify what is abnormal, and therefore requires veterinary assessment or investigation. This gives the rider, trainer, owner and vets the opportunity to take the necessary action.

Unlike radiography and scintigraphy, Infrared Thermographic Imaging does not involve radiation or radioactive materials and is therefore perfectly safe for the horse and the handler. In most cases the results of Thermographs can be provided instantly to enable vets, owners and riders to make prompt decisions on appropriate treatment.

## Equine Science Update

### Thermography predicts injuries

Thermography provides an excellent means of screening racehorses for early signs of injury, according to recent research in the USA.

Thermography gives a visual representation of the surface temperature of an object. Recent technological advances have made it a more reliable and convenient imaging technique. Over the past few years thermal imaging cameras have been specifically developed for use in horses. Consequently the use of the technique in horses has become increasingly popular.

Dr Tracy Turner, of the University of Minnesota, describes a two-year study, conducted with colleagues Jennifer Pansch and Julie Wilson. "We wanted to show that the technique could provide meaningful results in a practical situation," says Turner. "We also wanted to find out how well the thermographic findings agreed with the trainers' concerns and with the vets' findings."

During the first year of the study they carried out 225 exams on 45 horses from 7 different trainers. Examinations were performed weekly for ten weeks. They recorded 20 standard images for each horse, which they then analysed to identify abnormalities. Then they compared their findings with the veterinary record of each horse.

The thermographic findings correlated well with the trainers concerns. In 79 of the 225 exams the trainer had specific concerns about the horse. The area of concern coincided with the area highlighted by the thermography in 82% of cases.

Twenty-three of the 45 horses had to be examined by a vet for lameness problems. In all but one case the thermography findings agreed with the vet's findings. The exception was a case of exertional rhabdomyolysis (tying up).

Nine horses had to stop training because of injury. Three had chip fractures in the knee and one a chip fracture of the fetlock joint. Two had tendinitis. Three horses had soreness affecting more than one bone or joint. In each of these horses, thermography detected the area concerned at least two weeks before the injury was diagnosed.

In the second year of the study they carried out 461 thermal studies on 50 horses from 10 different trainers.

Trainers had specific concerns in 127 of 461 horses. Not only did thermography correctly identify the site of the problem in 95 % of those cases, it did so 2-3 weeks before the trainer became concerned. So, using this technique it was possible to alert the trainer to potential problems.

Twenty of the 50 horses underwent veterinary examination for lameness. Thermography correctly predicted the site of injury in nineteen cases (95%). Obvious changes in thermographic pattern were invariably associated with significant problems (bone chips, stress fractures, and tendinitis.)

Nine horses had an abnormal thermal scan of the tendons; eight later developed tendinitis. The thermogram revealed abnormalities in the fetlock of twenty nine horses; fifteen later developed problems at the fetlock. Of fifteen horses with suspicious scans of the knee, ten developed problems. In contrast, forty-one horses had abnormal thermograms of the hock but only nine developed problems in that area.

The number of horses showing abnormal back muscle thermography patterns remained fairly constant throughout the year with the exception of two peaks. These changes coincided both with a recent reworking of the track and coincided with increased complaints of horses not working well.

Turner points out that, as with any other imaging modality, thermography takes experience to interpret. For example, the lame leg may actually appear colder because of transfer of the load to the good leg. He stresses the benefit of repeated exams to detect subtle changes. It's not so much "hot spots" as change in thermal pattern that causes concern.

Several factors influenced the results. The level of work definitely affected the appearance of abnormalities. "Chronic, rested cases are the most difficult to see anything in. I will get them to ride the horse first before I examine it," says Turner. "Maximal exercise was a problem. We found that we couldn't examine them within two hours. The feet remained hot for 24 hours after a gallop."

"We also learned that liniments and icing did not affect the detection of signs - provided that the horse had both legs treated in the same way.

"What about bandaging artifacts?" As long as both legs were bandaged, you could see through the changes" he adds. "If both legs are bandaged we take them off and scan straight away and read through the changes. Over time as we built up the trainers trust in the technique, they removed bandages for 2 hours before - which made the changes much easier to read."

"I use the technique on a daily basis in my clinical work" reports Turner. "Thermography is ten times more sensitive than my hands at detecting changes. I use it at the end of my physical exam - so that I have stressed it as much as I can to accentuate the changes. It doesn't tell you what is going on. It tells you where to go and look more closely."

He found that trainers readily accepted the technique for what it is, a tool to better manage the horse through the season.

He concludes that "This provides an excellent method for screening racehorses and detecting injuries before they become clinically apparent. So it should be useful in assessing and screening other sport horses during training."

*For more details see: Thermographic assessment of racing Thoroughbreds. TA Turner J Pansch J Wilson. Proc Conference on Equine Sports Medicine and Science 2002 p207*

© Copyright Equine Science Update 2002-2006

# Horses in Colour: The role of Thermal Imaging in the Equine industry

Joanna Robson, DVM, CVSMT, CMP, CVA, SFT  
Inspiritus Equine, Inc. Napa, CA 94558  
[www.InspiritusEquine.com](http://www.InspiritusEquine.com)

## Abstract

Thermal imaging isn't new to the horse world, though it's finding its renaissance in today's performance-charged equine industry. As thermal camera technology has improved, and standardization in equine imaging is introduced, this diagnostic tool is finding its niche in equine veterinary practice and the horse industry as a whole. Thermal imaging is helping to identify and pinpoint hidden injuries and inflammation, aids in saddle-fitting, may prevent breakdowns and determine whether a horse is ready to compete, provides insight during pre-purchase examinations, and also benefits farriers and general practitioners. With trained technicians and veterinary interpretation, thermal imaging is finally taking its deserved place among traditional radiography and ultrasound as a useful, non-invasive, diagnostic modality. Thermal imaging provides a whole new vision of equine health.

## Introduction

Thermal imaging was introduced to the equine industry in the 1960s, primarily as a screening tool for racetracks and performance horses. However, due to expensive and rudimentary cameras, little knowledge of correct imaging technique, and a lack of understanding how to correctly interpret the images, the technology soon fell out of favour both with veterinarians and human medical professionals. In the 1980s, however, the U.S. courts accepted thermography as documented evidence of pain<sup>1</sup>. And while the American Academy of Orthopaedic Surgeons released an advisory statement in 1991 stating that: "A review of the literature indicates a lack of specificity, reliability, and reproducibility for this technique<sup>2</sup>, "the use of thermography steadily continues to increase in human screening for cancer, work-related injuries, and other physiologic processes. The use of thermal imaging is also increasing in the equine industry. So what has changed?

## The Industry

The equine industry has undergone a major transformation over the past three decades. Now a multi-billion dollar industry with huge financial stakes both in and out of the barn, there is great demand for the latest and greatest in diagnostic equipment. There is also a more significant emphasis on alternative medicine and non-invasive modalities.

Horse owners and trainers are well educated, and many expect the same quality of care for their animals that they would for their own human family members. "At the 1996 Olympic Games in Atlanta, where there was millions of dollars' worth of equipment available to the equestrian teams, the most-requested diagnostic tool was thermography. It was fast. It was portable. It was non-invasive. It could detect injury sites before they became lameness problems, and could guide practitioners to specific anatomic areas for study using other diagnostic techniques. And it was extremely accurate when used by an experienced

---

<sup>1</sup> Strickland, C. Thermography: A hot images and a hot topic. *The Horse*, Oct 2001, 853.

<sup>2</sup> Ibid

practitioner."<sup>3</sup> The demand for thermal imaging has boomed with the industry's economic surge.

There are an estimated 9.2 million horses in the United States<sup>4</sup>. The equine industry directly produces an average of 40 billion dollars annually, with the average GNP for the equine industry at 112 billion dollars or more<sup>5</sup>. Consider that in addition to the buying and selling of horses, the equine industry also encompasses training and boarding, trucks and trailers, competition revenue and sponsorships, entertainment, tack and equipment, feed, bedding, supplies, veterinary and dental care, alternative medicine modalities (acupuncture, chiropractic, bodywork, laser), farriery, and more.

The average horse owner is a middle-aged Caucasian female, with an annual income of \$36,000-\$60,000 per year (range by state)<sup>6</sup>. Purchasing a horse may be free (adopting rescues) to millions of dollars (racehorse yearlings and proven performers). After the initial purchase, a horse owner may spend upwards of \$10,000-\$30,000 per year to house, feed, train, and compete or ride her horse<sup>7</sup>. The National Horse Council provides statistics on horse population and ownership. Currently, the largest horse populations by state are Texas, California, Florida and Kentucky, with other Midwestern states on the rise<sup>8</sup>. There are many different disciplines within the horse world. Dressage, show jumping, reining, cutting, polo, racing, endurance, roping, barrels, and halter are only a few examples of the many different equine sports world-wide. The Federation Equestre Internationale is the international governing body for all horse sport, and there are many national organizations divided by breed or discipline, as well as pony club and therapeutic riding programs.

## Equine Health

In this high-stakes financially and emotionally charged equine world, protecting and caring for our equine companions is of utmost importance. The field of equine sports medicine is rapidly expanding with new advances in injury prevention, diagnosis, and treatment. In order to understand the ever-increasing role of thermal imaging in equine health, we must first examine the types of injuries we encounter in horses, and how they occur.

The horse is a prey animal, and though the small 3-toed prehistoric creature has evolved into the single-hoofed animal we know today, the flight response hasn't much evolved. "Horses have a very well-developed "fight or flight" mechanism and when anything happens to startle them, they often react first and think later. If they get caught in something such as a fence or barn wall, their first instinct is to leave; often without regard to whatever body part happens to be caught at the time. Therefore, horses have a well-deserved reputation as being accident-prone<sup>9</sup>." We have domesticated horses through the millenia for food and milk, packing, fighting wars, and transportation. But today's horse is predominantly used for sport and recreation, with heavy emphasis on churning out prospects and starting them at younger ages, making them more readily available for the sale barns. These animals that are designed to be moving and grazing constantly, now find themselves limited to our artificial environment of a 10'x10' box stall, twice daily feeding, and limited daily exercise. Horses, through flighty instinct, boredom, extreme size, great energy, increasing sports demand, and often fragile genetics, will injure themselves – it is only a question of when and how badly.

---

<sup>3</sup> Brown, K. Thermography: Diagnosis tool for horses. *The Horse*, Oct 2001, 490.

<sup>4</sup> National economic impact of the US horse industry, [www.horsecouncil.org](http://www.horsecouncil.org)

<sup>5</sup> Equine nutrition and health. [www.alltech.com](http://www.alltech.com)

<sup>6</sup> [www.horsecouncil.org](http://www.horsecouncil.org)

<sup>7</sup> Ibid

<sup>8</sup> Ibid

<sup>9</sup> ACVS General Wound Management [www.acvs.org](http://www.acvs.org)

Equine injuries could be subdivided into: accidental, human-induced, and physiologic or naturally occurring. Accidental injuries would include lacerations and scrapes, broken bones and soft-tissue injuries that occur as a result of a horse playing, falling or slipping, encountering sharp objects (broken fencing, nails, etc.), trailer traumas, or being kicked or injured by another horse. Human-induced problems include all those that are caused by our intentional or unintentional ignorance. For example, the soring of gaited horses (intentional application of a caustic substance to exaggerate a desired movement), ill-fitting tack and saddles, poor trimming and shoeing, imbalanced or forceful riding, and failure to recognize signs of early lameness that results in more significant disease and injury. Physiologic or naturally occurring diseases are those such as arthritis or kissing spine, laminitis (inflammation of the hooves), age-related changes (hormonal), cancer, or infections (EPM, EHV-1). These categories are often overlapping. Man's forceful riding on uneven ground will lead to tendon and ligament tears, or early arthritis. Man's racing of a young horse with an undiagnosed hairline fracture, may result in a fatal "accidental" breakdown.

Some specific major common diseases or pathologies resulting in decreased performance, lengthy rehabilitation, or retirement include:

#### List A

- Suspensory ligament tears
- Tendon tears
- Sacroiliac problems
- Arthritis
- Muscle pulls, tears, strains, avulsions
- Damage from ill-fitting saddles and tack, imbalanced riders
- Kissing spine, other primary spinal lesions
- Fractures
- Cervical problems
- Nerve damage
- Circulatory problems
- Infection/abscess
- Hoof problems – ringbone, laminitis, imbalanced hooves

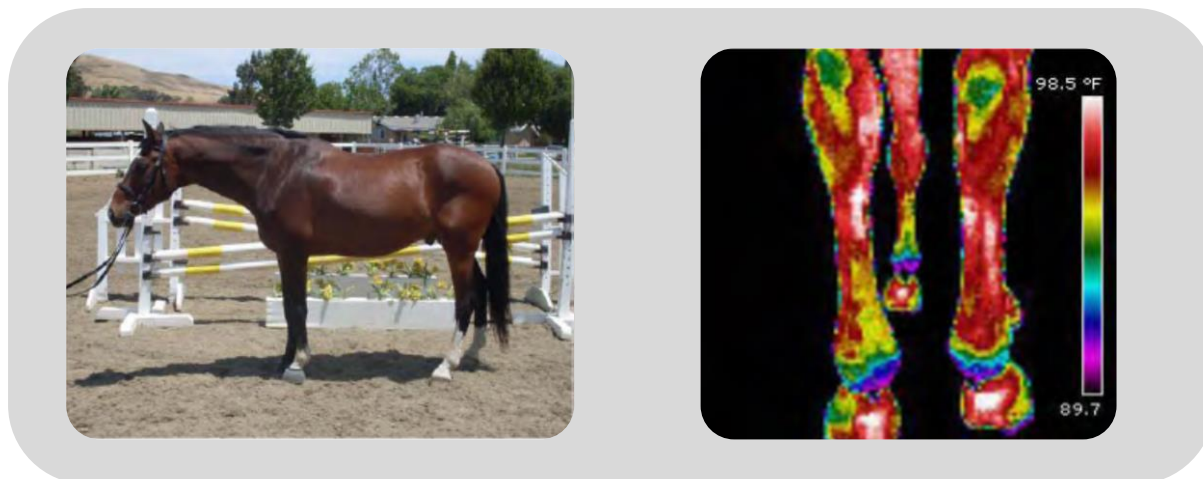
This list is important, as each of these problems causes circulatory or inflammatory changes that can be detected with a thermal imaging camera!

With the significant amount of time and money invested in the performance horse, any one of the above conditions can be catastrophic for both the owner and the animal.

Advances in veterinary medicine have resulted in significantly improved detection and treatment of these diseases, but at a generally significant financial and emotional cost to the owner. Why? Because current diagnostic modalities are aimed at diagnosing the problem once it has started and lameness is detected. But **PREVENTION** and early detection are the keys!

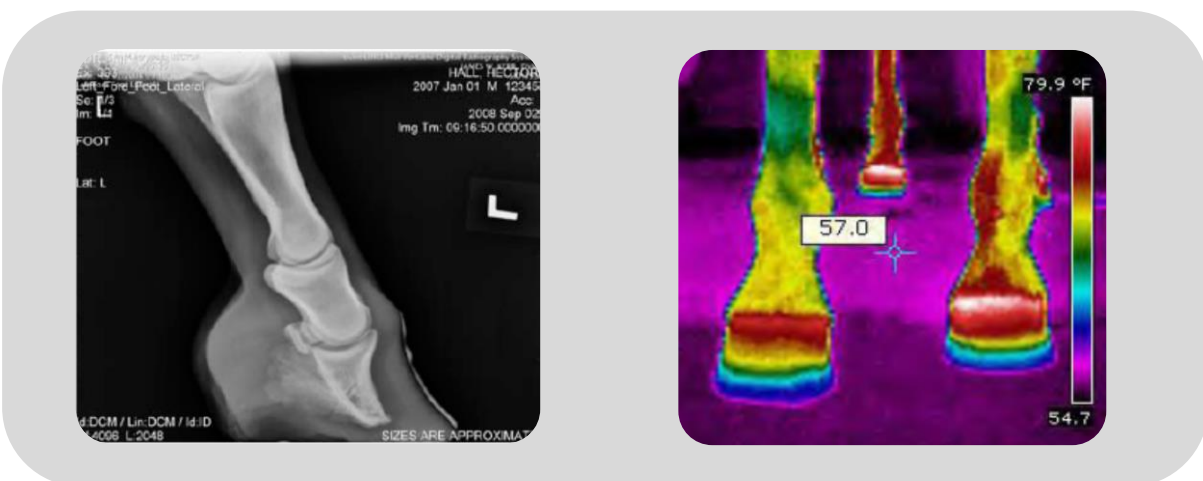


**Below:** “Laddie” has a lameness, but his owner is unsure of how to proceed with diagnostics to determine where and what the problem is. Thermal imaging scan reveals bilateral heat increase on the hindlimbs, which is then diagnosed with ultrasound as bilateral suspensory ligament disease.



## The Modalities

The major difference between traditional diagnostic modalities, such as ultrasound, and thermal imaging, is that one is anatomic, while the other is physiologic. An anatomic diagnostic modality will show a specific lesion or problem in an anatomic structure at a static moment in time. A physiologic modality such as thermal imaging cannot show a specific anatomic lesion, but does show a physiologic change in bloodflow that helps to localize a lesion and more easily shows changes over time. Let’s examine the diagnostic modalities currently available, and how they compare.



**Above Left:** On the left is a radiograph of a horse with a club foot. This is an “anatomic” modality as radiographs show a specific anatomy and pathology.

**Above Right:** A thermal image of a horse’s front feet, showing a “physiologic” difference in the circulatory patterns between the two.

Table 1 below illustrates the modality, what problems it detects, average cost in dollars, and advantages and disadvantages of each.



Table 1

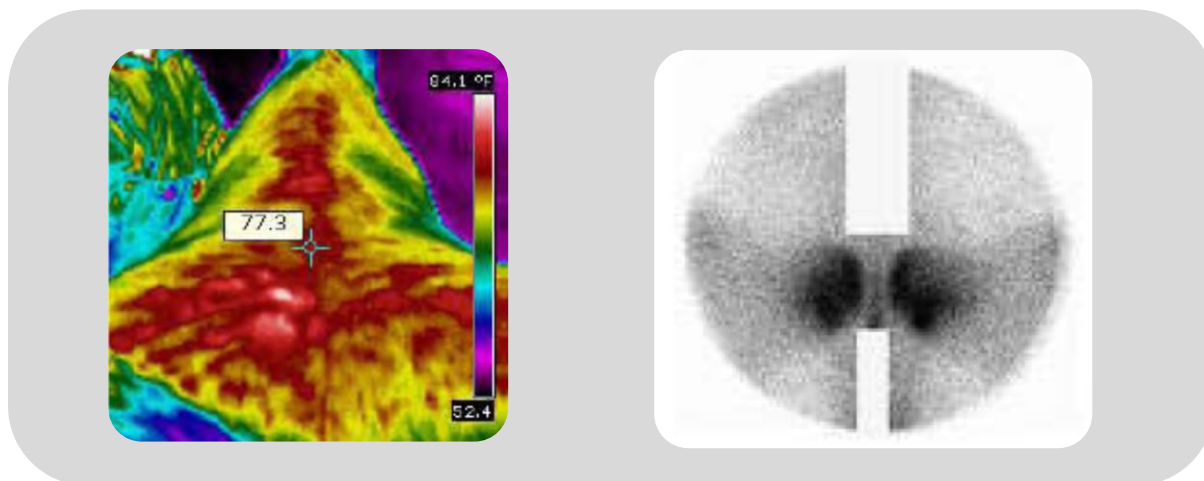
Modality	Detection	Cost	Advantage	Disadvantage
MRI	Soft tissue and bone	\$1200-\$3000	Specific, anatomic	Expensive, requires anaesthesia
CT	Soft tissue and bone	\$1200-\$3000	Specific, anatomic	Expensive, requires anaesthesia
Nuclear scintigraphy	Bone and some soft-tissue structures	\$500-\$2000	Whole body, sensitive, physiologic	Not specific, will require follow-up diagnostics; usually 3 days in hospital, invasive
Ultrasound	Soft tissue, some bone	\$100-\$300 per region	Specific, anatomic	Limited by region, may require sedation and clipping
Radiographs	Bone, some soft tissue (if swollen or affected)	\$100-\$300 per image or region	Less expensive, good quality now with digital radiographs	Limited by region, may require sedation, radiation exposure
Thermography	Bone and soft-tissue	\$100-\$300 for total body scan, often includes veterinary interpretation	Full body evaluation, non-invasive, early detection of problems BEFORE clinical signs, Physiologic	Correct preparation is necessary for a good evaluation; artifacts may alter images, often requires follow-up diagnostics
Veterinarian's lameness evaluation	General	\$150 plus regional blocks	Considered the standard "first step", important general baseline	Often requires follow-up diagnostics, not always sensitive or specific

Based on the table above, we can see that thermal imaging stands out as one of only 2 whole body modalities, and is by far the most cost-effective whole body imaging available. Thermography is non-invasive, and is also the most effective "preventative" modality through its ability to detect temperature changes indicative of early inflammation or circulatory disruption. In fact, thermal imaging has repeatedly demonstrated signs of soft-tissue injury, such as tendon or ligament damage, two weeks BEFORE any clinical signs of lameness, or heat or swelling were detected<sup>10</sup>.

Thermal imaging should be considered as much a diagnostic tool, as it is a preventative maintenance tool. As mentioned in the introduction, the human medical field has routinely rejected thermography because of the need for, and ready availability of, specific imaging modalities (MRI, CT, etc.). However, in the equine industry, general anaesthesia carries inherent risks, and while most clients want the best for their horses, expense does play a role in the diagnostic process. Equine insurance companies will often cover thermographic imaging, which also makes it a more accessible tool to horse owners.

---

<sup>10</sup> Brown, K. Ibid.



**Above left:** Image is a thermal scan showing increased heat over the sacroiliac/tuber sacrale region of a horse (arrow).

**Above right:** Image is a nuclear scintigraphy image of the same region on a different patient (from Langfordvets.co.uk).

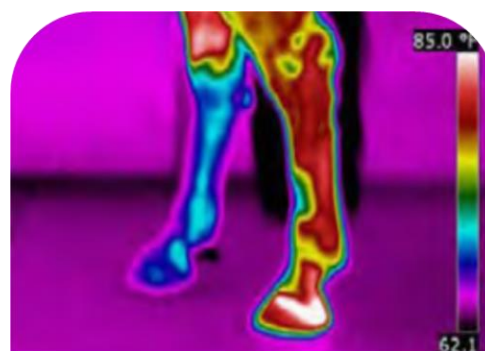## Roles of Thermography

Thermal imaging is useful throughout the equine industry, but the tool finds its niche in a few key areas: injury detection and prevention, pre-purchase evaluations, saddle-fitting, and farriery. The injuries and diseases listed earlier produce inflammation or changes in bloodflow that are directly related to radiant heat emitted from the body surface. Likewise, a lack of circulation may also be an indicator of disease, and muscle atrophy, nerve damage, scar tissue, and circulatory disruption may also be detected with thermal imaging.

Pre-purchase evaluations are often a veterinarian's nightmare. Making decisions about whether or not a horse is suitable for purchase based on a general physical examination, radiographs of specific joints, and perhaps an endoscopy, misses a large percentage of the patient – all the soft tissues and regions that cannot be palpated or evaluated with a traditional modality.

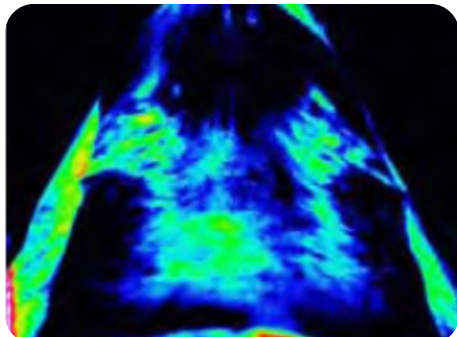
Professional reputations are at stake, and equine malpractice insurance premiums are through the roof as horse purchase prices soar. Utilizing a non-invasive WHOLE BODY scan as part of a pre-purchase evaluation to determine whether there are other "hidden" lesions present can make a significant impact on the buying and selling of horses. Thermography has the potential to become a standard practice in the equine buying and selling game due to its being non-invasive and generally inexpensive. The cost to benefit ratio of the scan in a pre-purchase evaluation is one of its greatest attributes.

Saddles and equipment play a significant role in equine performance. Imagine running a marathon in shoes two sizes too small – ouch! Now explain to a horse how he's going to jump a 6-foot-high brick wall in a saddle that vice-grips his shoulders! Many clients need the



**This horse had NO outward signs of lameness. The "blue leg" is a significant circulatory or nervous system abnormality. Without thermography, how would this ever be discovered?**

objective image evidence of the inflammation that is caused by their ill-fitting tack to be spurred into making positive changes, especially when the sales representative has “assured” them of a correct fit. Rider balance also plays a significant and often under-discussed role in equine performance. Thermal imaging can help to demonstrate the difference between the influence of tack, and the influence of an imbalanced rider, on the horse beneath.



**Left:** Thermal image of a horse's back during a saddle-fitting seminar. The saddle put increased pressure over the left side of the horse's back, and impinged on the left thoracic spine. Thermography is a useful saddle-fitting tool, but should be combined with a certified saddle-fitter for best results.

Farriers are also taking great notice of thermal imaging capabilities. From evaluating hoof imbalances, to diagnosing laminitis and abscesses, this tool can help to stage disease or locate problems. Navicular syndrome and laminitis both have a huge financial impact on the equine industry, and thermal imaging is playing a role in the research in both diseases.

Other thermal imaging niches include track and arena footing scans and the eliminating of soring and other unethical practices (tail blocking, nerving, etc.). The FEI currently sanctions thermal imaging as a tool to determine whether a horse is fit to compete, or if its legs have been tampered with.

## Success with thermal imaging


### What are the most important factors for success with equine thermal imaging?

Standardization and correct interpretation are crucial to continued acceptance of thermal imaging as a diagnostic modality. Thermal imaging failed in its inception in the equine industry because of a lack of standardization and understanding of the technology and its correct use. Thermal imaging was compared to radiographs and ultrasound, which could show specific lesions; and was therefore discarded because of its lack of specificity. Now, with significantly better technology, and recognition of the importance of standardization, thermal imaging is taking its rightful place in equine diagnostics.

Standardization and correct patient preparation are imperative to both minimize artifacts, and to maximize gain through blood flow and residual inflammation (or lack thereof). Artifacts such as moisture and sweat, dirt, caustic substances, bandages and blankets, can and will immediately negate the correct interpretation of a scan. Environmental control cannot be over-emphasized as critical to a successful scan. Sunlight, radiant heat from metal roofs or barn siding, fans and breezes, and the flooring of the barn (mats, dirt, concrete, etc.) can alter images and destroy a scan. Having a clean and dry patient in an environment free of drafts, direct sunlight, or moisture, are keys to the success of your imaging scan, and to the repeatability and reliability that thermal imaging requires for continued acceptance in the veterinary and equine industries.

Interpretation of the images is the other half of a successful imaging equation in a modality dependent on symmetry. In keeping with state veterinary practice laws, thermal imaging interpretation must be done by a licensed VETERINARIAN.

Even more important, in addition to a solid understanding of patient anatomy, an interpreting veterinarian must have an understanding of thermal imaging technology to correctly relate the images with possible physiologic changes. Of all the injuries bulleted in List A, thermal imaging is able to locate every one through physiologic changes emitting heat or altered circulation.



Though the images are not able to tell the interpreter the specific nature of the lesion, the sensitivity of the camera to detect temperature changes related to disease is key to its success. Changes greater than 1-2 degrees F are considered significant<sup>11</sup>, but asymmetry and a deviation from normal anatomic structures are major factors in image interpretation.

## Conclusion

Thermal imaging is a diagnostic tool that is gaining more widespread interest and recognition in the equine industry. Infrared camera technology has significantly improved, and understanding the technology is leading to improved interpretation of thermal imaging in biological systems. It is incorrect to tout thermal imaging as a replacement for traditional diagnostics. Thermal imaging's strength is that it can significantly enhance traditional modalities through improved localization of injury and disease, and has an adjunctive role in highlighting lesions otherwise missed with traditional imaging modalities.

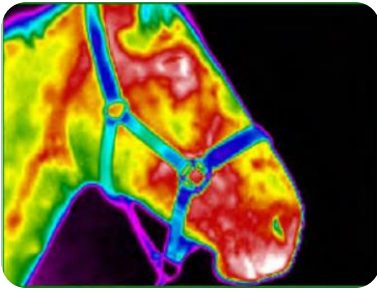
Correct training is imperative. To learn more about adding equine thermal imaging to your business, please visit [www.equineir.com](http://www.equineir.com) to view their training modules.

For more resources on thermography in the equine industry, please visit [www.thehorse.com](http://www.thehorse.com) or [www.pubmed.com](http://www.pubmed.com) and search "equine thermography".

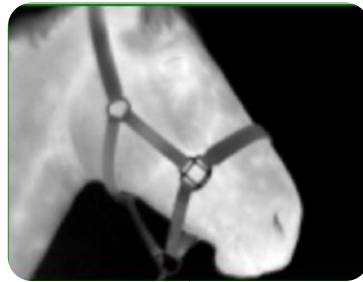
---

<sup>11</sup> Ibid

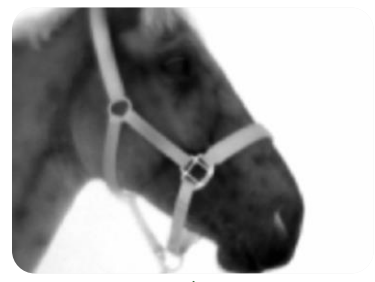## Thermal Colour Packets



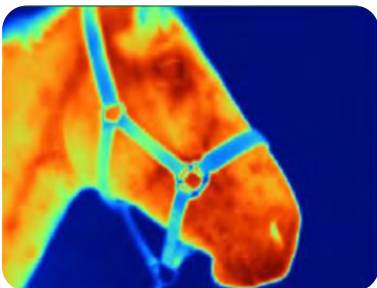
High Contrast



Greyscale



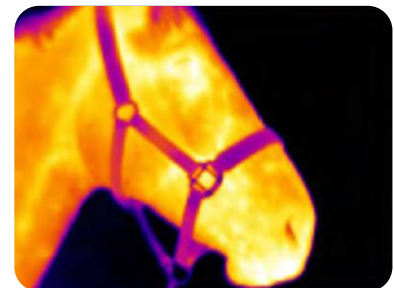
Greyscale Inverted



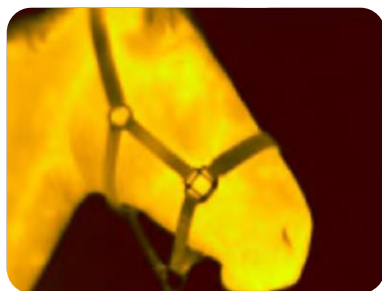
Blue Red



Hot Metal



Ironbow




Amber



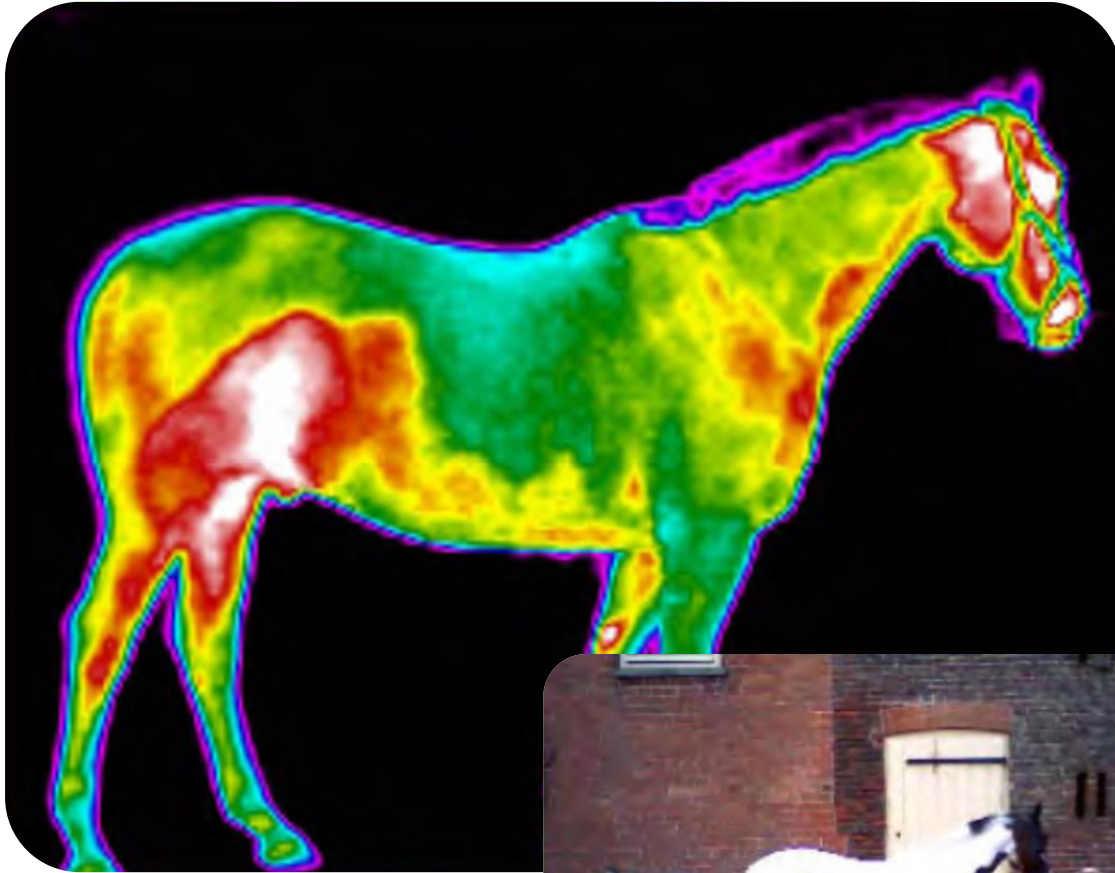
Amber Inverted



## Nearside (Left) View




## Offside (Right) View







## Posterial (Back) View



## Arterial (Front) View



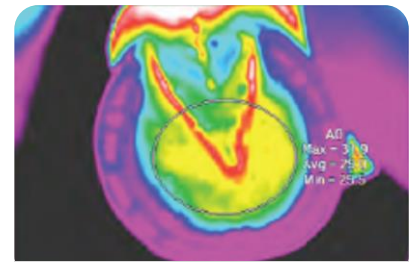
## Gallery



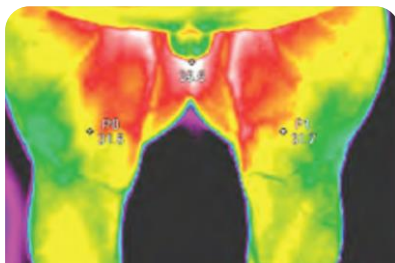
Nearside Forelimbs 100% Thermal Image. C/w temperature spots.



Lower Forelimbs in 'Picture in Picture' mode. Showing good symmetry.




Base of Hoof. 100% Thermal Image. C/w average/min & Max temperature formation.




Hind Limbs & Stifles in 100% Thermal Image. C/w Comparison Temperature & Highest Temperature. Good Symmetry.



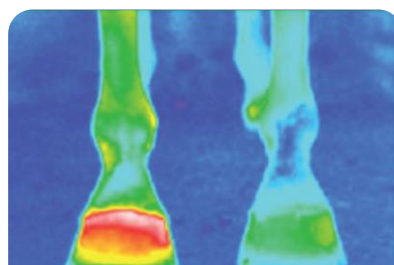
Lower Forelimbs in 50/50 Thermal/Visible



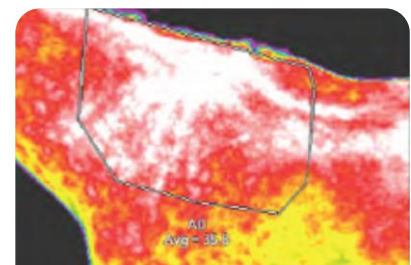
Back Imaging in 'Picture in Picture' mode. C/w Highest Temperature spot.



Offside Neck/Head in 'Picture in Picture' mode



Lower Forelimbs in 100% Thermal Aspect before temperature analysis. Showing irregular thermal patterns.



Nearside Neck & Shoulders - 100% Thermal Image with Avg. temperature formation. Showing large area of heat.



## Benefits

### Features

- Non Invasive
- Humane
- Relaxing Without Stress
- Minimal Contact
- Own Environment
- 20/30 Mins Duration

### Essentials: The Equine

- Clean, Brushed
- No Bandages or covers
- Tail Tied
- Unexercised
- Relaxed
- Square/Balanced

### Essentials: The Environment

- Indoor Location: without sunlight/rain
- Dry, Clean & Clear
- Even Floor Surface
- Draught Free Environment
- Adequate Space: 5/6 Foot



Q&A




Hand Inspection



Imaging Front




Imaging Hind



Imaging Nearside




Imaging Offside



Imaging Stifles



Imaging Back



Imaging Hoof



Imaging Head

## Maximising Thermal Imaging Accuracy

The results achieved from a thermal imaging can be very accurate, and can report significant differences between 0.1°C.

In order to maximise the accuracy a number of conditions (artefacts) should be met prior and during the survey.

The report may at some point be viewed by your vet who will have to assess artefacts influence on the results. We try to minimise these, as much as possible, by insisting on the following:

### Pre Survey Horse Preparation

- Keep horse indoors for 1hr (Avoid all sunlight and windchill)
- No exercise (1hr prior to survey)
- Horse should be clean, dry and free of dirt (Legs/Hooves)
- Pick Out Hooves
- Remove all Rugs/Covers/Bandages & Leg Covers (1hr prior to survey)
- Mane & Tail plaited and/or bandaged preferable
- Avoid application of Creams or Liniments
- It is preferable for horse to be evenly clipped, without long length areas.

### Survey Conditions: Environment

- Clean/Sweep required Indoor Location (free of bedding)
- Dry and Even Floors are preferable
- Indoor draught free stable/barn/shed where possible
- Avoid where possible sunlight and windchill to area
- No power is required for our Equipment.

### During Survey

- Experienced Horse handler required for
- Pre Inspection Q & A (history of horse)
- Handling and Positioning
- Picking up Feet

*During winter temperatures it is preferable to have had some exercise / during summer temperatures it is preferable to image in early mornings/evenings*

*Imaging will not be conducted in temperatures above 29°C (85°F)*

*The survey is non-invasive and does not put the horse through any stress.*

*Each survey can take 20-30 mins dependant on the conditions/handler/temperament of the horse.*

# Survey Summary

## Pre Survey Summary

EquineInfrared.co.uk

The examination can take 20/30 minutes, dependant on achieving correct positioning.  
The Handler must be capable of balancing, squaring and stepping the horse's legs for correct imaging.

LOCATION: .....

DATE: ..... TIME: .....

### General

Name of Horse ..... Breed .....

Age of Horse ..... Sex Male  Female

Height ..... h/h

Colour ..... Markings .....

Female Mare >3 / Filly <3

Male Gelding / Stallion >3 / Colt <3

Young Foal / Weanling / Yearling

### Personality

Temperament .....

Sensitivity (to touch) .....

### Use of Horse

Leisure Use .....

Competition Use .....

Working Use .....

### Daily Routine (if any)

Usual .....

Last 24 Hours .....

### Current Injuries/Concerns

i.e. Lameness .....

### Historical Injuries







i.e. Scars .....

### Reason for Scan

Details
Vet:
Farrier:
Saddler:
Other:

Owners Details
Owners Name:
Address:
Email Address:
Contact No:

Conditions			
The Horse			
	Y	N	
Last Exercise (1hr)	<input type="checkbox"/>	<input type="checkbox"/>	Creams
Brushed	<input type="checkbox"/>	<input type="checkbox"/>	Medication
Clean	<input type="checkbox"/>	<input type="checkbox"/>	Eaten
Bandages (1hr)	<input type="checkbox"/>	<input type="checkbox"/>	Tail Tied
Rugs	<input type="checkbox"/>	<input type="checkbox"/>	Clipped
Hand Check			
Forelimbs:		Hindlimbs:	
Neck, Back & Hind:		Date:	
Shod:			
Comments:			
Environment			
Ambient Temp			
External :		Internal :	
Internal Conditions			
Dry Floor	<input type="checkbox"/>	<input type="checkbox"/>	Even Floor
Clear Floor	<input type="checkbox"/>	<input type="checkbox"/>	Draughts

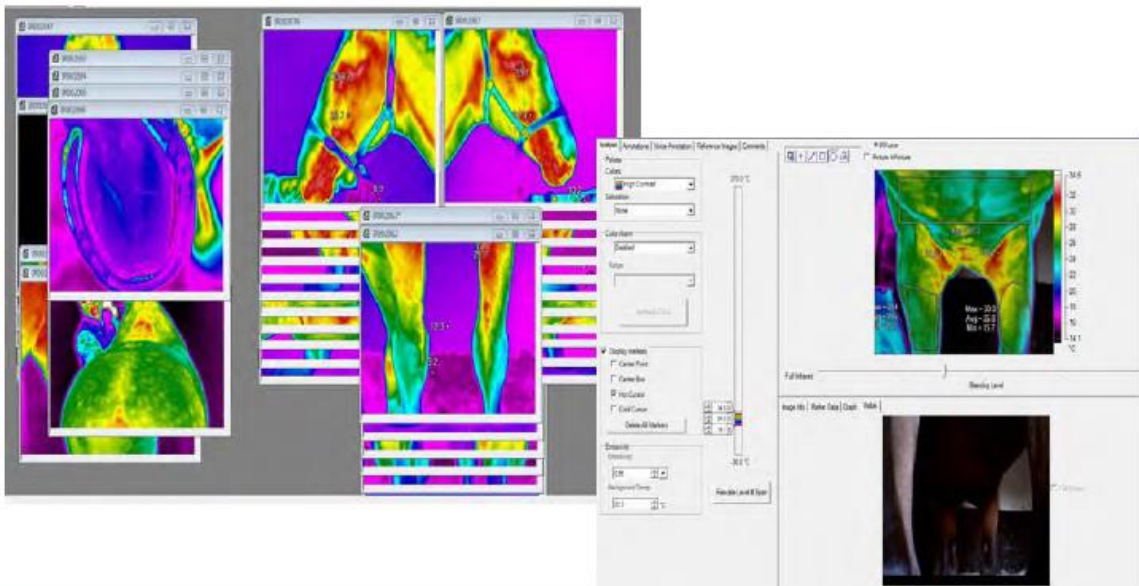
Perspectives	
FRONT	HIND
	
10	7
NEARSIDE	OFFSIDE
	
9	9
BACK	HOOVES
	
4	4

Disclaimer: The thermography is an aid to diagnosis only, it is illegal for a thermographer to provide diagnosis, and any findings or concerns should be referred to your vet for diagnosis.

Confidentiality: EquineInfrared treat all information and results as highly confidential, we can assure only the owners and trusted carers will receive information, and all results are stored safely in the companies secure file storage system.

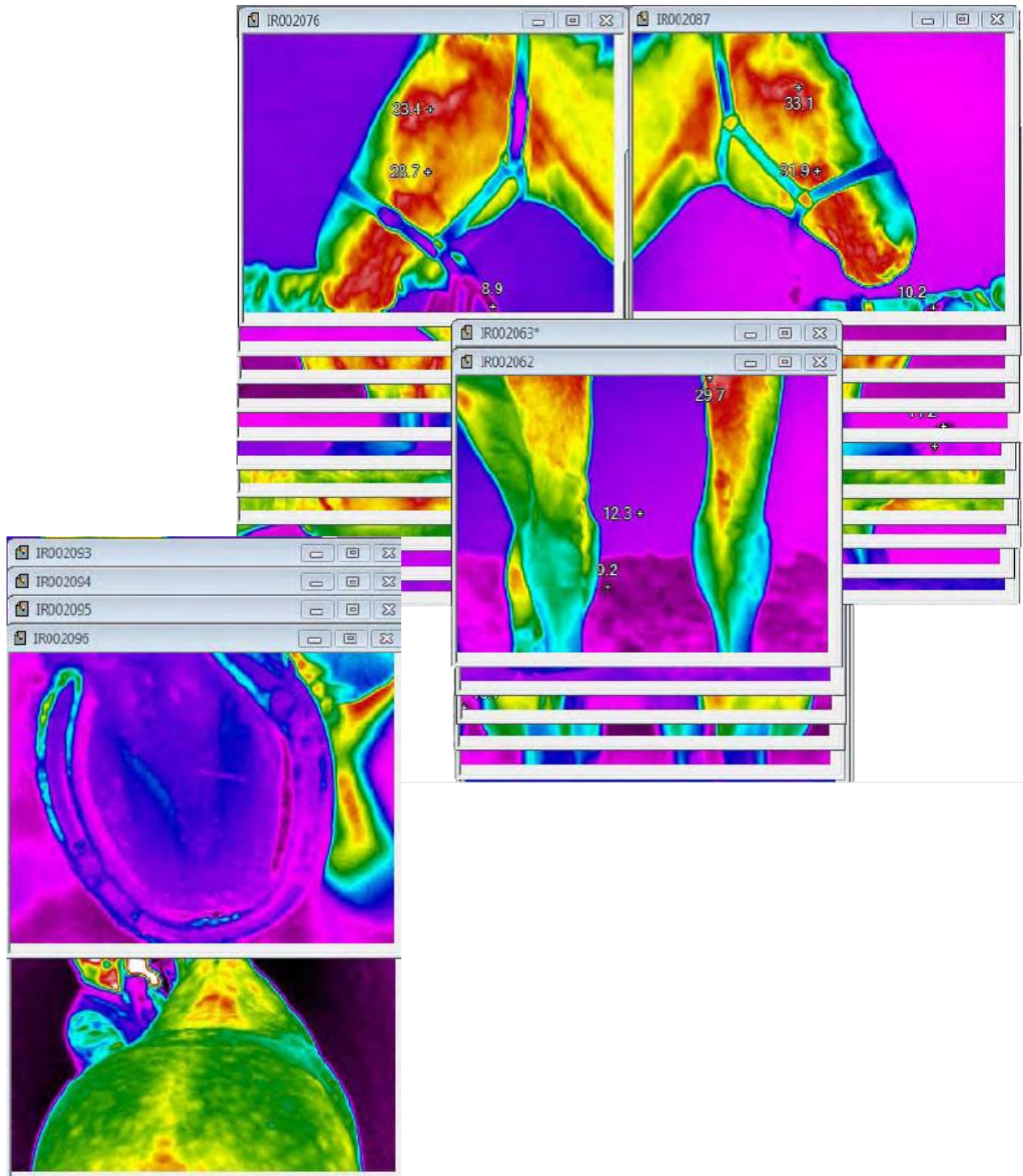


# Analysis & Reports

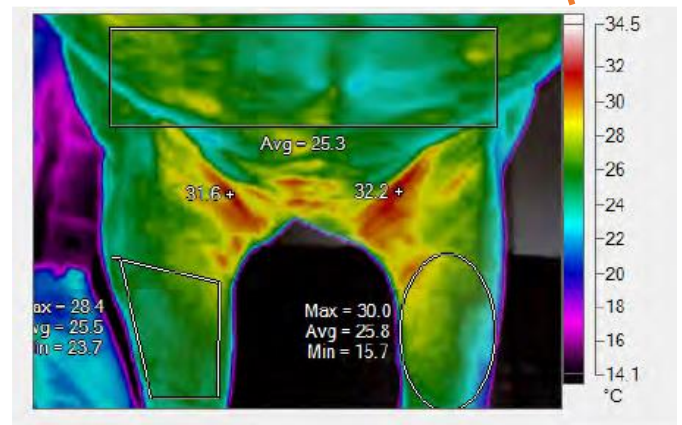
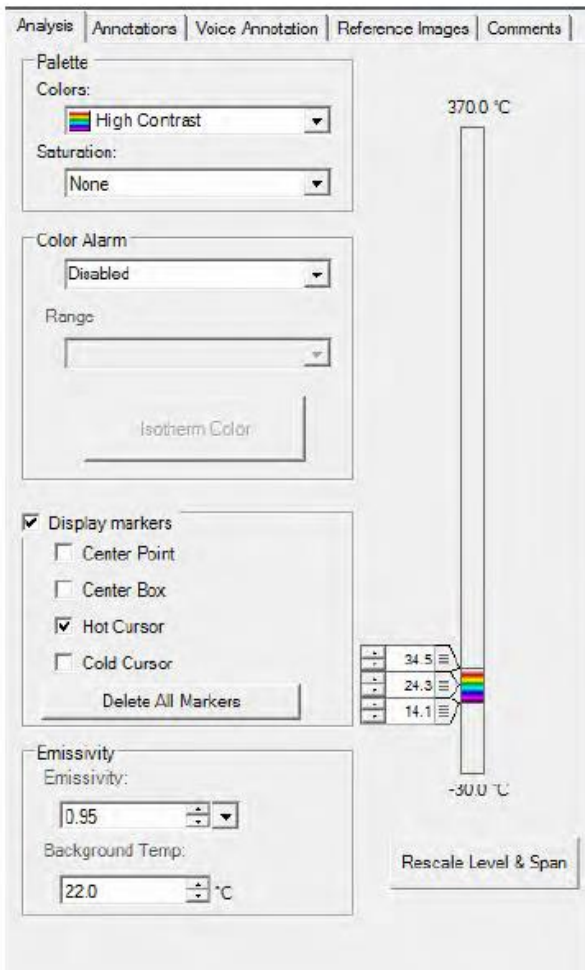
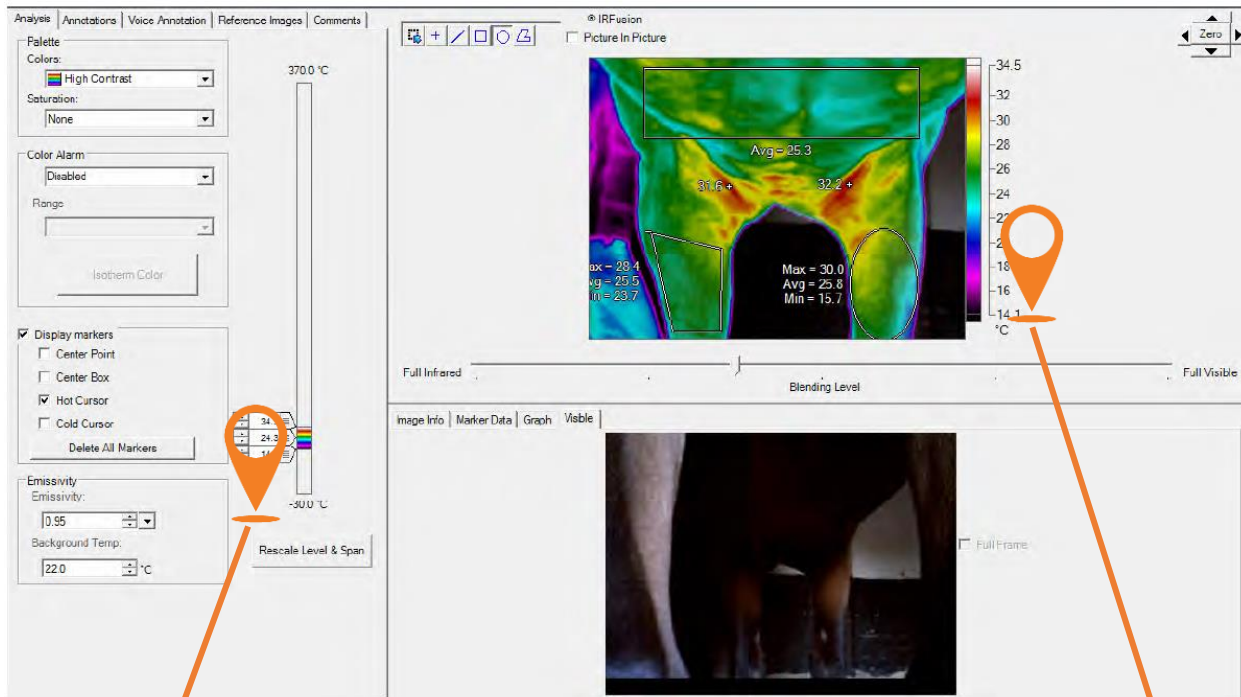




## Software Screenshot: All Images Grouping



# Software Screenshot: Analysing Image by Image



## Summary of Services

### Diagnostic/Base Scan Visits

These visits are ideal for first time users of thermography on their horse. It will usually be prompted by concerns over the horse in competition, or while active leisure riding. It will help confirm problems exist, and where the problem is located. In some instances may highlight unknown issues. As a full scan is conducted every time, this acts as a base scan for comparison in future examinations.

### Continuous Monitoring

These services are geared towards the discerning owner who appreciates the benefits of preventative and predictive maintenance, and benefits it has on overall medical costs.

#### Annual Wellness Program (monthly/quarterly/bi-annual)

This service is ideal for the individual who wants to give their horse the best possible care, at all times. The service can be split in to various periods to suit your concerns or care level.

#### In Competition Program (6 monthly visits)

This service is ideal for those who compete with their horse, and want to ensure their horse is in the best condition to take part during the competition season, and have peace of mind that injuries are not being sustained and ignored.

#### Rehabilitation Program (as required weekly/monthly)

An ideal service whose horse is under treatment or forced box rest, this service operates by monitoring the progress of healing over the expected duration, and may sometimes facilitate earlier return to activity.

### Specialist Visits

#### Saddle Check and/or Rider Profiling

Thermography can tell you if the saddle you use is a correct fit, and may be a cause for poor performance or behaviour, together with analysis of the rider in the saddle for correct posture and riding position. This service can be added to the usual inspection, but will require the horse to be ridden after the standard inspection.

#### Pre-Sale or Purchase Surveys

If you are selling or purchasing a horse, the reassurance that there are not underlying issues the horse's health. This service can benefit the seller in proving soundness to a potential buyer, or give piece of mind to the buyer of the investment they may make.

#### Competition Monitoring at race/event

This service is geared to the competition horse and how it muscles and ligaments are coping with the competition. It is carried out at the event, unlike all the other services, and aims to get a before and after competition view of the horses physical condition.

#### Complimentary Visits (vet/farrier/saddlery/physio)

It may be beneficial to have thermographic imagery carried out before, during, or after the professional services you already use. This may be requested by you or the practitioner as an aid to their prognosis.

## 24 hour Emergency Call Out

Equine ownership can be a stressful occupation, and sometimes you just want to know, and know NOW! This service may help you decide your next course of action, based on the pain you think your horse is in, and at the time you want it done.

## Full Thermographic Survey

Whatever the circumstances we generally conduct a full thermographic scan which involves approx. 40 images covering all key areas of the horse's anatomy. Each scan takes approximately 20-30 mins.

All prices below take the above into account and include the following.

- On site Imaging of Horse 40 images over 30mins
- Full Colour Printed Report (within 7 days) (On site computer analysis is also available see below.)
- Online Screen View Explanation
- Safe and Confidential File Storage
- Online Portal (view your horses historical reports) available 2011

**Note:** All services below are based on one location.

All prices quoted are inclusive of travel within a 30 mile round trip of HU10 area. There after a 39p per mile will be added to quote.

## Diagnostic Visits \* payment on completion at site

<b>Single Horse visit:</b>	£60
<b>Twin Horse Visit:</b>	£50
<b>3 – 5 horses:</b>	£45
<b>5 – 10 horses:</b>	£40
<b>10 – 20 horses:</b>	£35
<b>20 – 30 horses:</b>	£30
<b>30+ horses:</b>	£25

## Continuous Monitoring \*payment in advance of all program visits

<b>Annual Wellness Program (monthly/quarterly/bi-annual):</b>	£30/£40/£50
<b>In Competition Program (6 monthly visits):</b>	£35
<b>Rehabilitation Program (as required weekly/monthly):</b>	£35/£40

**Specialist Visits** \* payment on completion at site

<b>Saddle Check and/or Rider Profiling</b>	add: £20
<b>Pre-Sale or Purchase Surveys:</b>	£60
<b>Competition Monitoring at race/event:</b>	£ 300 full day £175 half day
<b>Complimentary Visits (vet/farrier/saddlery):</b>	£60
<b>24 hour Emergency Call Out:</b>	£150

**On Site Computer Analysis** add - £25

**Payment Terms:** Cheque or Cash only

**Hours of Availability:** Mon - Fri 6am – 8pm | Sat - Sun 8am – 6pm

(Excluding emergency call out service)